

# Systemic Inflammatory Response Syndrome after Massive Extravasation into the Pleural Space of Contrast Medium during Supracostal Percutaneous Nephrolithotomy

Diogo Sobreira Fernandes<sup>1</sup>, Daniel Reis<sup>2</sup>, Maria Fátima Martins<sup>1</sup>, Vitor Cavadas<sup>2</sup> and Humberto S Machado<sup>1\*</sup>

<sup>1</sup>Department of Anesthesiologia, Centro Hospitalar do Porto, Portugal

<sup>2</sup>Department of Urologia, Centro Hospitalar do Porto, Portugal

\*Corresponding author: Humberto S Machado, Department of Anesthesiologia Centro Hospitalar do Porto, Largo Prof. Abel Salazar, 4099-001 Porto, Portugal, Tel: 351935848475; E-mail: [hjs.machado@gmail.com](mailto:hjs.machado@gmail.com)

Received date: Jan 16, 2015, Accepted date: Feb 11, 2015, Published date: Feb 16, 2015

Copyright: © 2015 Fernandes DS, et al. This is an open-access article distributed under the terms of the Creative Commons Attribution License, which permits unrestricted use, distribution, and reproduction in any medium, provided the original author and source are credited.

## Abstract

Percutaneous nephrolithotomy is indicated for renal stones larger than 2 cm and upper ureteral stones not amenable to retrograde management. Supracostal access may enable better access to the entire collecting system and even be preferential in some cases, although having a higher risk of pleural or lung injury, resulting in hydrothorax or pneumothorax. We report a case of a patient who developed a massive hydrothorax during surgery. In this particular case the hydrothorax was mainly composed of iodixanol (visipaque®) isosmolar nonionic contrast media. We assume that this was the reason why a subsequent systemic inflammatory response syndrome (SIRS) was observed. There is no reference in the literature to a prolonged SIRS associated to a hydrothorax mainly composed of nonionic contrast media following a supracostal percutaneous nephrolithotomy.

**Keywords:** Chest wall; Intraoperative complication; Hydrothorax; Immune response; Prone position

## Case report

A 54-year-old woman was hospitalised for a scheduled left supracostal percutaneous nephrolithotomy. She complained of periodic urinary tract infections and during etiologic investigation a radiopaque kidney stone located in the medial superior calyceal group, estimated by abdominal computed tomography in 2.2 cm was diagnosed. There was no past history concerning the respiratory and cardiovascular systems. She was chronically medicated for anxiety and depression and she referred mild dyspepsia. On admission she had completed a two-week period of ciprofloxacin because of an *Escherichia coli* ampicillin resistant urinary tract infection. She was not aware of any medication allergy. Fourteen years before she was submitted to a total hysterectomy and bilateral anexectomy to treat a benign pathology. Her physical examination, preoperative haemogram and biochemistry study were normal.

The patient was classified as being an ASA II, and balanced general anaesthesia with endotracheal intubation was performed. Intraoperative prophylactic cefoxitin 2 g at the beginning of procedure and every two hours 1 g dose was given. After retrograde ureteropyelography and insertion of a ureteral catheter, the patient was positioned in ventral decubitus and renal access between the 11th and 12th ribs was obtained. The supero-lateral calyx was successfully punctured under fluoroscopic control and tract dilation was carried out with a balloon. After injection of methylene blue through the ureteral catheter, progression until the stone was not possible because of a narrow calyceal infundibulum. Superomedial calyceal puncturing was attempted, but with no success. From the initial renal puncture to the detection of the hydrothorax around 50 minutes had passed. During the surgery it was observed a small but gradual increase on

peak airway pressure, a slight decrease in the pulmonary compliance on the spirometry curve, and also an increase requirement of higher inspired oxygen concentrations. The consecutive arterial blood gasometries reflected a sustained hypercapnia, a respiratory acidosis and an increase on the alveolar to arterial oxygen gradient, suggesting increasing shunting. After the stone removal attempts stopped, a thoracic x-ray was obtained and a massive hydrothorax was identified, as shown in Figure 1.

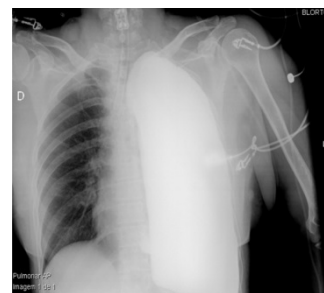


Figure 1: A thoracic x-ray

Hemodynamic instability was not observed. A temporary thoracic drain (12 French nephrostomy) was immediately inserted in the pleural cavity under fluoroscopic control, with drainage of 1.3 L of a viscous hematic fluid. We estimate that around 0.5 L of iodixanol (visipaque®) isosmolar nonionic contrast media were used during the procedure. The patient was awakened and extubated, but on admission at the post anesthetic unit care showed signs of respiratory distress, with a type 2 respiratory acidosis with acidemia (pH 7.189; PaO<sub>2</sub> 62 millimeters of mercury (mmHg); PaCO<sub>2</sub> 56.9 mmHg; HCO<sub>3</sub> 19.2 mmol/L). She also had anaemia, with initial blood haemoglobin

of 12.9 g/dL and at the end of the surgery of 10.7 g/dL (normal value range: 12-16 g/dL). She was transferred to the intensive care unit (ICU) with a high concentration oxygen mask, and scheduled for a successful removal of the temporary pleural drain and insertion of a number 27 French thoracic drain on the left 5th intercostal space.

The patient stayed at the ICU during one day, and was transferred to an intermediate care unit with haemodynamic stability, but a systemic inflammatory response syndrome (SIRS) (fever,  $23.08 \times 10^9/L$  leucocytes (normal range:  $4.5-11 \times 10^9$ ) with 95% of neutrophils (normal range: 40-70%), c-reactive protein (CRP) 443 mg/L (normal range: 0.0-5.0 mg/L). Gram negative prophylactic antibiotics (initially ceftriaxone and then colistine tazobactam) and analgesia with morphine were initiated. The thoracic drain was clamped and removed after two days. During those 48 hours only 0.5 L of serous-haematic-fibrin fluid had drained. The patient was transferred to the urology ward with normal arterial blood gasometry with 2 L oxygen nasal cannula. The patient stayed there during 22 days with an oscillating SIRS (asthenia, fever, leukocytosis with neutrophilia, high CRP, reactive thrombocytosis with maximum of  $1,229 \times 10^9/L$  (normal range:  $150-350 \times 10^9/L$ ) unresponsive to large spectrum antibiotics (meropenem), but always with haemodynamic stability and decreasing dependence on oxygen. During that time the patient did two blood and urine microbiologic screens that were sterile. Since it was noted an abnormal left inferior pulmonary field auscultation a thoracic computed tomography was performed and a loculated pleural empyema was found. A controlled radiologic drainage was done, but only a scarce amount of sterile purulent content was removed, so only microbiologic study was possible. Bacterial growth was not identified in this culture.

Seven days after this procedure the patient was discharged from hospital asymptomatic and with a normal haemogram and biochemistry.

## Discussion

The pleural violation in the form of hydrothorax is an established complication of the supracostal approach in percutaneous nephrolithotomy, especially if done above the 11th rib. A chest x-ray is recommended after this approach. Nevertheless, it is a safe and effective technique with acceptable morbidity in selected cases of complex renal upper ureteral, and upper caliceal stones [1-6]. Longer operative time and higher ASA scores are associated with the risk of more severe postoperative complications [5-9].

The incidence of any adverse reaction to iodinated contrast media (ICM) is about 15% with an estimated risk of about 3% to nonionic ICM. Adverse reactions to ICM can be divided into hypersensitivity and physiochemotoxic reactions. Hypersensitivity reactions are idiosyncratic and can be further divided into immediate and delayed reactions. Immediate reactions develop within one hour of administration and they tend to mimic an anaphylactic (allergic) reaction [10-14]. Delayed reactions become apparent at least 30 minutes after but within 7 days of the ICM injection, and they are most often cutaneous [13,15].

Physiochemotoxic reactions are nonidiosyncratic, dose dependent and include renal toxicity, hyperthyroidism, vasovagal reactions and local tissue damage caused by contrast extravasation. They appear to relate to the ionic and osmotic nature of the ICM [10-14].

We noticed that there is no reference in the literature to a prolonged SIRS associated to a hydrothorax following a supracostal percutaneous nephrolithotomy [1-8]. This hydrothorax was composed of a significant amount of contrast media. The microbiologic screenings suggested that there was no infectious disease, and we virtually covered all the potential respiratory, urinary and nosocomial bacterial foci. Therefore, we could be in the presence of a physiochemotoxic nonidiosyncratic adverse reaction to the medium contrast extravasation into the pleural cavity. Iodixanol (visipaque®) is an isosmolar nonionic contrast medium and produces adverse reactions only rarely [9-11]. Nevertheless, they are described especially if great amounts are extravasated, in this case into the pleural cavity. The pathogenesis of such adverse reactions probably involves direct cellular effects; enzyme induction; and activation of the complement, fibrinolytic, kinin, and other systems [9].

## Conclusion

The SIRS observed in this patient had an atypical course and the microbiological screenings were negative. It was also unresponsive to broad spectrum antibiotic therapy. Therefore, a rare and not previously described reaction to visipaque® should be considered as a possible cause for this postoperative complication. Furthermore, it could motivate a reflection whether this contrast is as innocuous as we think.

## References

1. Kekre NS, Gopalakrishnan GG, Gupta GG, Abraham BN, Sharma E (2001) Supracostal approach in percutaneous nephrolithotomy: experience with 102 cases. *J Endourol* 15: 789-791.
2. Munver R, Delvecchio FC, Newman GE, Preminger GM (2001) Critical analysis of supracostal access for percutaneous renal surgery. *J Urol* 166: 1242-1246.
3. Gupta R, Kumar A, Kapoor R, Srivastava A, Mandhani A (2002) Prospective evaluation of safety and efficacy of the supracostal approach for percutaneous nephrolithotomy. *BJU Int* 90: 809-813.
4. Yadav R, Aron M, Gupta NP, Hemal AK, Seth A, et al. (2006) Safety of supracostal punctures for percutaneous renal surgery. *Int J Urol* 13: 1267-1270.
5. Labate G, Modi P, Timoney A, Cormio L, Zhang X et al (2011) On Behalf Of The Croes Pcnl Study Group J. The percutaneous nephrolithotomy global study: classification of complications. *J Endourol* 25: 1275-1280.
6. Semins MJ, Bartik L, Chew BH, Hyams ES, Humphreys M, et al. (2011) Multicenter analysis of postoperative CT findings after percutaneous nephrolithotomy: defining complication rates. *Urology* 78: 291-294.
7. Aakmakaya S, Salihoğlu Z, Demiroglu S, Kose Y (2008) Unrecognized Massive Hydrothorax During Supracostal Approach For Percutaneous Nephrolithotomy. *The Internet Journal of Anesthesiology* 15: 789-791.
8. Jou YC, Cheng MC, Shen CH, Lin CT, Chen PC (2009) Delayed Hydrothorax after Percutaneous Nephrolithotomy. *JTUA* 20:190-191.
9. Siddiqi NH, Lin EC (2014) Contrast Medium Reactions. *Medscape*.
10. Singh J, Daftary A (2008) Iodinated contrast media and their adverse reactions. *J Nucl Med Technol* 36: 69-74.
11. Cohan RH (2012). *ACR Manual on Contrast Media*. Version 8. American College of Radiology.
12. Andreucci M, Solomon R, Tazanarong A (2014) Side effects of radiographic contrast media: pathogenesis, risk factors, and prevention. *Biomed Res Int* 2014: 741018.
13. Madox TG (2002) Adverse Reactions to Contrast Material: Recognition, Prevention, and Treatment. *American Family* 66: 7.
14. Carver E, Carver B (2012) *Medical Imaging: Techniques, Reflection & Evaluation (2ndedn.)* Churchill Livingstone ELSEVIER.

**Citation:** Fernandes DS, Reis D, Martins MF, Cavadas V, Machado HS (2015) Systemic Inflammatory Response Syndrome after Massive Extravasation into the Pleural Space of Contrast Medium during Supracostal Percutaneous Nephrolithotomy. *J Anesth Clin Res* 6: 502. doi:[10.4172/2155-6148.1000502](https://doi.org/10.4172/2155-6148.1000502)

- 
15. Loh S, Bagheri S, Katzberg RW, Fung MA, Li CS (2010) Delayed adverse reaction to contrast-enhanced CT: a prospective single-center study comparison to control group without enhancement. *Radiology* 255: 764-771.